

Copper, an abandoned player returning to the wound healing battle

Published April 2021



This book chapter describes the healing and antimicrobial properties of copper, addressing the molecular mechanisms of enhanced wound healing by copper-oxide impregnated dressings.

Impregnation of copper-oxide microparticles in wound dressings allows continuous release of copper ions, resulting in the protection of the wounds from pathogens and enhances wound healing.

The antimicrobial efficacy of copper was demonstrated against the following microorganisms:

- Escherichia coli,
- Enterococcus faecalis,
- Enterobacter aerogenes,
- Klebsiella pneumoniae,
- Staphylococcus epidermis,
- Methicillin-resistant Staphylococcus aureus (MRSA)
- Candida albicans.

Copper stimulates many factors, which are important for angiogenesis, keratinocytes and fibroblasts proliferation, epithelization, collagen synthesis, and extracellular matrix remodeling .

Clinical cases show a clearance of infection, induction of granulation and epithelialization of necrotic wounds, reduction of post-operative swelling inflammation, and reduction of scar formation in wounds treated with copper-oxide impregnated dressings.

“We show the positive outcome at all wound healing stages of using the copper impregnated wound dressings, indicating the neglected critical role copper plays in wound healing.”

Borkow, G., Melamed, E. (2021) Copper, an abandoned player returning to the wound healing battle. In: Scars and Keloids. Ed: Shahin Aghaei; IntechOpen London: 5 Princes Gate Court, London, SW7 2QJ, UK

Read the full paper online: <https://www.intechopen.com/chapters/75798>

Copper, an Abandoned Player Returning to the Wound Healing Battle

Gadi Borkow and Eyal Melamed

Abstract

Copper has two key properties that endow it as an excellent active ingredient to be used in the “wound healing battle”. First, copper plays a key role in angiogenesis, dermal fibroblasts proliferation, upregulation of collagen and elastin fibers production by dermal fibroblasts, and it serves as a cofactor of Lysyl oxidase needed for efficient dermal extracellular matrix (ECM) protein cross-linking. Secondly, copper has potent wide-spectrum biocidal properties. Both gram-positive and gram-negative bacteria, including antibiotic resistant bacteria and hard to kill bacterial spores, fungi and viruses, when exposed to high copper concentrations, are killed. Copper has been used as a biocide for centuries by many different civilizations. Impregnation of copper oxide microparticles in wound dressings allows continuous release of copper ions. This results not only in the protection of the wounds and wound dressings from pathogens, but more importantly, enhances wound healing. The article discusses the molecular mechanisms of enhanced wound healing by the copper oxide impregnated dressings, which include in situ upregulation of pro-angiogenic factors and increased blood vessel formation. It also includes clinical cases showing clearance of infection, induction of granulation and epithelialization of necrotic wounds, reduction of post-operative swelling inflammation and reduction of scar formation, in wounds when they were treated with copper oxide impregnated dressings. We show the positive outcome at all wound healing stages of using the copper impregnated wound dressings, indicating the neglected critical role copper plays in wound healing.

Keywords: copper oxide, wound dressings, wound healing, angiogenesis, extracellular matrix, chronic wounds

1. Introduction

Wounds normally heal in finely balanced, efficient, and ordered sequence of repair events distinguished by four distinct, but overlapping, phases: Hemostasis, Inflammation, Proliferation and Remodeling [1, 2]. These coordinated cellular and molecular events involve numerous processes such as cell proliferation, migration and differentiation. All of these processes demand a continued and efficient supply of oxygen and nutrients, due to the increased cellular biosynthetic activities. Following wounding, the altered microenvironment, such as the reduced oxygen supply, initiates the release of factors by epidermal cells,

fibroblasts, macrophages and vascular endothelial cells, all of which stimulate neo-vascularization. The secreted factors include vascular endothelial cell growth factor (VEGF), fibroblast growth factor (FGF) and transforming growth factor (TGF)- β . VEGF is believed to be the most prevalent, efficacious, and long-term signal that is known to stimulate angiogenesis in wounds. TGF- β , especially TGF- β 1, is also a key cytokine that regulates the production and secretion of elastin and collagen [3]. Fibroblasts, which attach to fibrin and integrin cables, produce and secrete collagen and elastin that become cross-linked, forming the dermal extracellular matrix (ECM). This allows the restoration of the structure and function to the injured tissue [4, 5].

1.1 Chronic wounds

Chronic wounds or “hard to heal wounds” are characterized by extensive loss of the integument, clear necrosis, or signs of circulation impairment either localized or more extensive, usually in the limbs, or in pressure areas, leading to extensive loss of substance. Chronic wounds seem to be detained in one or more of the phases of wound healing, and some chronic wounds may never heal or may take years to do so. These wounds have lost the fine balance needed for wound repair, leading to chronic non-healing ulcers, associated with morbidity and mortality due to tissue inflammation and infection [6]. Chronic wounds are usually associated with systemic pathologies [7] that cause ischemia, a restriction in blood supply to tissues. Ischemia occurs in diabetic patients due to atherosclerosis as well as microangiopathic disease [8], in chronic venous ulcers due to chronic venous insufficiency [9], in patients with autoimmune disease or under immunosuppressive drug therapy due to vasculitis [10] and in pressure sores due to necrosis of the integument [11]. Chronic wounds cause patients severe emotional and physical stress and create a significant financial burden on patients and the whole healthcare system. Chronic wounds require special attention and wound care.

1.2 Involvement of systemic copper in wound healing

Copper is an essential mineral involved in many of the physiological processes in all body tissues [12, 13], including the skin and integumentary system [14]. Many of the finely balanced wound healing repair mechanisms are dependent on their interaction with copper (thoroughly reviewed in [6]). This includes, Platelet-derived growth factor (PDGF), involved in the hemostasis phase of wound healing, [15, 16]; VEGF and angiogenin, key growth factors that stimulate angiogenesis, an essential process during the Proliferation Phase [17–23]; secretion of collagens (types I, II, and V), HSP-47 and elastin fiber components (elastin, fibrillins) by dermal fibroblasts during the Proliferation and Remodeling Phases [16, 24, 25]; activity of Lysyl oxidase (LOX) needed for efficient extracellular matrix (ECM) protein cross-linking between elastin and collagen [26]; stabilization of the skin ECM once formed [27, 28]; modulation of integrins by differentiated keratinocytes during the Remodeling phase [29], and Matrix metalloproteinases (MMPs, mainly MMP-1, MMP-2, MMP-8, MMP-9) and the serine proteases (human neutrophil elastase, HNE) are the major groups of proteases involved in the wound healing process. It is thus not surprising that copper chelation delays wound closure [30]. Copper is also a cofactor of superoxide dismutase, an antioxidant enzyme found in the skin that inhibits cellular oxidative effects, such as membrane damage and lipid peroxidation and protects against free radicals [19]. Copper is also a cofactor of tyrosinase, a melanin biosynthesis essential enzyme, responsible for skin and hair pigmentation.

1.3 Copper and wound infections

Infections of the wound may delay wound healing, cause wound deterioration and even cause failure of healing [31]. This may occur through several different mechanisms: consistent and high production of inflammatory mediators, metabolic wastes and toxins; tissue hypoxia; causing hemorrhagic and fragile granulation tissue; reducing fibroblast number and total collagen production; and interfering with reepithelization [32, 33]; reducing the available nutrients and oxygen needed by the host cells and causing neutrophils to be in an activated state producing cytolytic enzymes and free oxygen radicals [34]. In chronic wounds bacteria may be covered by biofilm and be protected from the host defenses and develop antibiotic resistance [31]. Thus, reducing the microbial contamination of wounds increases the capacity of the wound to heal.

Copper is also a needed mineral for the normal function of microorganisms [35]. However, the microorganisms need to carefully control the intracellular copper levels. This is since copper under anaerobic condition is found in the highly reactive cuprous form (Cu^{1+}), and as such it can readily react with the microbial proteins, causing disruption of the protein structures by forming thiolate bonds with iron-sulphur clusters [36]. Thus, above an exposure to a certain concentration of copper, microorganisms cannot cope with the excess copper and are killed [37, 38]. Several mechanisms for the potent biocidal activity of copper have been proposed, which include alteration of proteins and inhibition of their biological assembly and activity; plasma membrane permeabilization; and membrane lipid peroxidation [37]. In contrast to the resistant microbes that have evolved to antibiotics in less than 50 years of use, tolerant microbes to copper are extremely rare even though copper has been a part of the earth for millions of years. This lack of resistance to copper may be explained by the capacity of copper to damage in parallel many key factors in micro-organisms [37].

2. Cuprous oxide impregnated wound dressing

2.1 General description

Copper oxide impregnated wound dressings, hereafter called COD, have been cleared for treatment of acute and chronic wounds, including diabetic ulcers, pressure sores, and venous ulcers, by the USA FDA, EU and other regulatory bodies worldwide. The COD are soft, single use wound dressings composed of an absorbent highly absorbent needle punch layer and one or two external non-binding nonwoven orange polypropylene layers. All layers are impregnated with copper oxide microparticles. The orange external layer(s) is intended to be in contact with the wound bed. The wound dressings are provided with or without an adhesive contour, sterile, in a sterilization pouch (**Figure 1**). The non-adhesive wound dressings can be cut, trimmed or fold over according to the size and shape of the wound. The dressings can be used up to 7 days or until they are completely soaked with wound exudate.

2.2 Antimicrobial efficacy

The COD exert potent wide spectrum antimicrobial efficacy (>4 log reductions), including when the dressings are completely soaked with wound exudate surrogate for 7 days, as demonstrated by us and by independent laboratories using the AATCC Test Method 100. Furthermore, the potent antimicrobial efficacy is maintained even after 7 consecutive microbial inoculations for 7 consecutive days (**Figure 2**).




Figure 1.

Copper oxide impregnated wound dressings. The COD are composed of an absorbent layer and one or two external layers. The dressings are provided (a) with or (b) without an adhesive contour. The external layer (c, orange layer) is a non-adherent polypropylene layer placed in contact with the wound bed, which allows the passage of the wound exudates into the internal layer (c, beige layer) that absorbs the wound exudates. COD with two external layers (d) are more appropriate for application in wound cavities and deep wounds. All layers are impregnated with copper oxide microparticles (e, white dots) that endow them with potent biocidal properties.

The antimicrobial efficacy was demonstrated against the following microorganisms: *Escherichia coli*, *Enterococcus faecalis*, *Enterobacter aerogenes*, *Klebsiella pneumoniae*, *Staphylococcus epidermis*, Methicillin-resistant *Staphylococcus aureus* (MRSA) and *Candida albicans*. When compared with commercially available silver wound dressings, the antimicrobial efficacy was significantly higher than 9 out of the 12 silver dressings studied, and as good as 3 silver dressings (Figure 3, unpublished data).

2.3 Molecular mechanisms of enhanced wound healing

The capacity of copper to enhance faster closure of full-thickness wounds was demonstrated in several wound animal models, [30, 39, 40], including in diabetic mice [41].

The capacity of the COD to directly enhance repair of chronic wounds by supplying *in situ* essential copper lacking due to poor systemic blood supply (such as in diabetic ulcers), was demonstrated in a murine diabetic model considered to be the

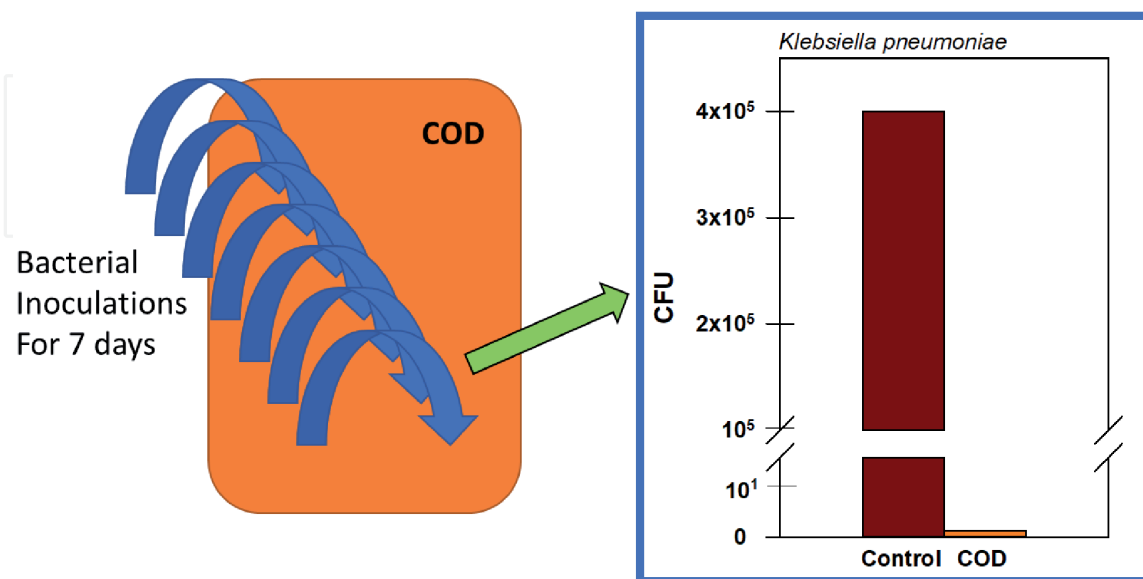


Figure 2.

Continuous antimicrobial efficacy of COD even after 7 consecutive bacterial inoculations. Duplicate COD were inoculated with $\sim 1 \times 10^5$ *Klebsiella pneumoniae* CFU for 6 consecutive days and incubated at 37 °C. On the seven days the CODs and a Control wound dressings without copper were inoculated with $\sim 4 \times 10^5$ CFU. After additional 24 hours of incubation at 37 °C, the bacteria were recovered and their viability determined. While no bacteria survived on the CODs, 4×10^5 viable bacteria were recovered from the control dressings.

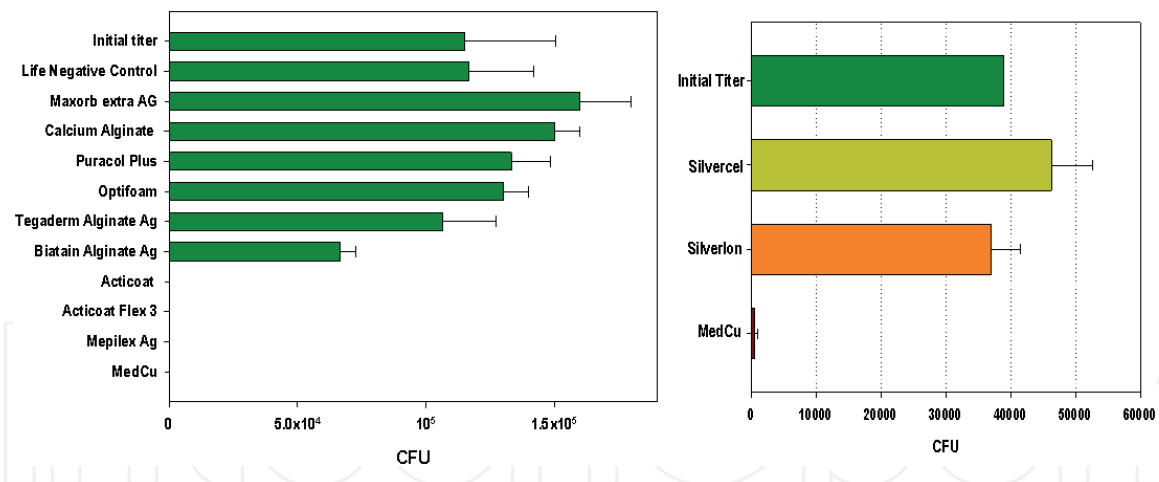


Figure 3. Antimicrobial efficacy comparison between the COD and commercially available silver dressings. The wound dressings were inoculated with $\sim 10^6$ (left panel) and 4×10^4 (right panel) MRSA CFU. After 1 hour of incubation at 37 °C the bacteria were recovered from the dressings and their viability was determined.

most suitable in diabetic wound healing studies [42]. Wounding and subsequent treatments were performed under aseptic conditions, so that the possible effects of the copper dressings would not be related to their biocidal properties.

A phenotype similar to diabetes type 2 in mice is achieved via a homozygous point mutation on the leptin receptor gene (LEPR) in the hypothalamus. Genetically engineered diabetic mice (db/db) show significant wound-healing impairment compared to wild-type mice [42]. Full-thickness single skin wounds were inflicted under sterile conditions on the dorsum of each animal followed by continuous dermal application of either COD or identical dressings without copper on the entire wound test site. Histological analysis of skin specimens taken from the diabetic mice treated with the COD 6, 12 and 17 days after wounding demonstrated a normal wound-healing process, including epidermal regeneration and granulation tissue formation, with numerous new blood vessels, chronic inflammatory infiltrate, generation of new hair follicles and sebaceous glands, and fibroplasia [41].

The very clear increase in angiogenesis in the copper treated mice was confirmed by immunohistochemistry staining using the Von Willebrand Factor that stains capillaries. Analysis of mRNA expression levels in the wound sites of 84 genes using real-time PCR gene-array analysis together with immunohistochemistry staining revealed the upregulation of several angiogenic factors, such as Vascular endothelial growth factor (VEGF). Based on the analysis performed a molecular mechanism was suggested in which a redox between cuprous oxide and cupric oxide generates hypoxia that induces the upregulation of Hypoxia-inducible factor-1 α (Hif-1 α) in the dermal layer, apparently in macrophages [41]. The upregulation of Hif-1 α then induces a chain of events, depicted in **Figure 4**, which lead to endothelial cell migration and proliferation, production of new blood capillaries (angiogenesis), immune cell recruitment, fibroblast migration, intense metabolism, increased secretion of extracellular matrix proteins, and increased epithelialization.

2.4 Clinical cases showing the enhancement of the COD at all stages of wound healing

The following cases illustrates the ability of COD to affect infection reduction, angiogenesis and granulation tissue formation, as well as epithelial tissue formation, in hard to heal wounds. In addition, we describe cases of reduction

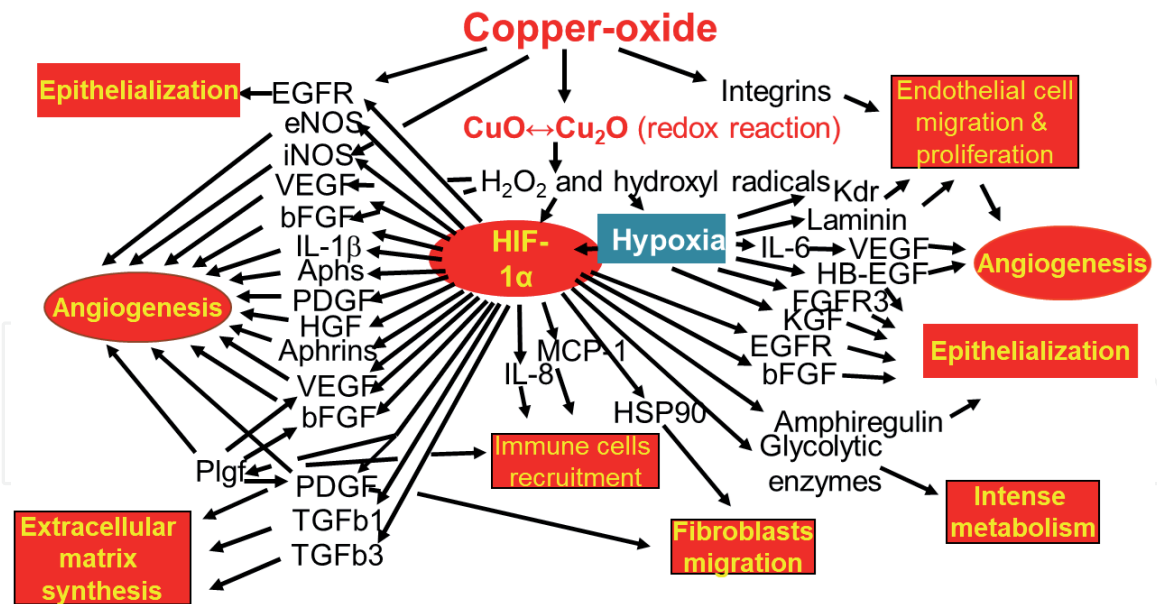


Figure 4. Molecular mechanisms of enhanced wound healing by COD. (based on the model published in ref. [41]).

of post-operative swelling and better post-surgery scar formation. All photos are published in the book with the patients' consent.

2.4.1 Clearance of infection, induction of granulation and epithelialization

Fifty-seven years old male, with history of non-insulin-dependent diabetes mellitus (NIDDM), suffering from ulcers in both feet, mainly on the right side (**Figure 5a**). The etiology was mainly due to vasculitis type reaction (acute leukocytoclastic vasculitis), with minor large arteries involvement (for which angiographic intervention with percutaneous opening of the superficial femoral artery was carried out). The patient was treated with high dose steroids, immunosuppressive medication (Azathioprine, Imuran) and broad-spectrum antibiotic treatment. The patient right foot worsened with development of necrosis mainly in the medial toes, with the infection spreading to involve the tendons and the plantar fascia. Deep ulcers were present over the medial aspect of the heel and the lateral aspects of the foot (**Figures 5a and b**).

The patient underwent surgery to debride the wound including 1st and 2nd ray amputation. Cultures taken at surgery yielded *Pseudomonas aeruginosa* resistant to quinolones and the patient was treated with Imipenem. Five days later the patient underwent trans-metatarsal amputation. The wound was partially closed to prevent a loose flap. Nevertheless, necrosis of the edges of the flap was seen few days following surgery (**Figure 5c**). Bedside debridement was carried out. At that time, culture taken from the second surgery revealed that the pseudomonas has now developed resistance to carbapenems and it was decided to stop the antibiotic treatment. The medial heel wound had at least 30% necrotic tissue. The lateral anterior wound had 80–90% necrosis (**Figure 5c and d**).

Trans-tibial amputation deemed to be the next step. WBC count was 18,000, which was an improvement from previous higher levels, and the CRP was 3.0 (normal <0.5). However, since the patient's overall condition was stable, it was decided to continue only with local wound care with COD. The dressings were placed deep in the plantar-fascial part of the amputation wound, on the edges of it and on the ulcers (**Figure 5d and e**). The dressings were replaced twice a week. Prontosan® irrigation was recommended during dressing change. No supplemental antibiotic was given.

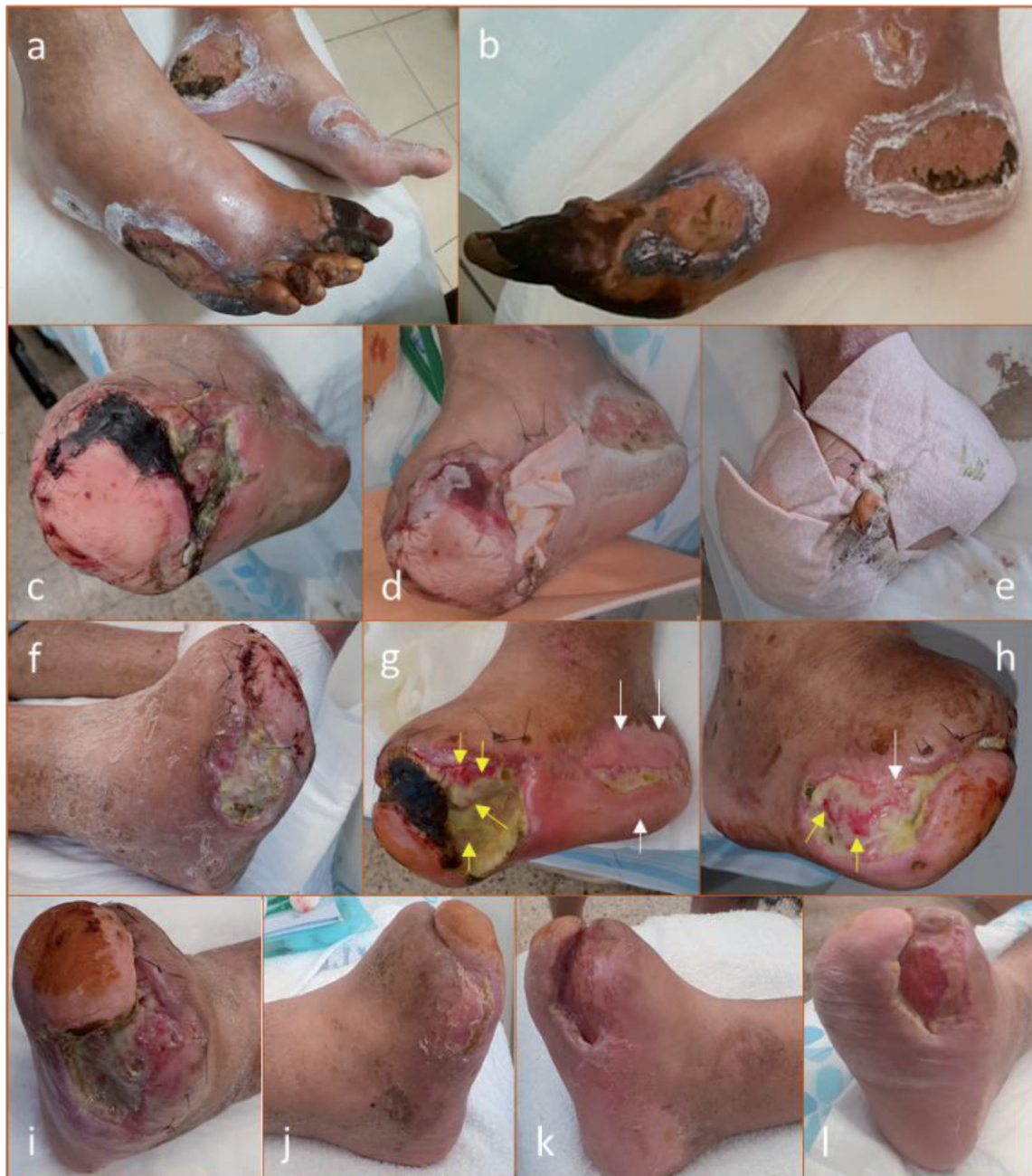

Figure 5. Clearance of infection, induction of granulation and epithelialization of necrotic wounds. *a.* Ulcers colonized with *Pseudomonas aeruginosa* were present on both feet, mainly on the right foot. *b.* The ulcers were present over the medial aspects of the heel and the lateral aspect of the foot. *c.* Two weeks following trans metatarsal amputation necrotic tissue was present on the edges of the partially closed flap. *d.* The COD dressings started to be used (Day 0) by placing them deep in the plantar-fascial part of the amputation wound and *e.* by covering the medial and lateral ulcers. *f.* One week later, a reduction in the necrotic tissue and beginning of granulation tissue was observed in all wounds. *g* and *h.* After 2 months of COD treatment there was clear epithelialization (white arrows) in the lateral and medial ulcers and granulation tissue formation (yellow arrows) in the lateral and medial ulcers and in the main bulk of the amputation wound that can be seen through the remaining thin necrotic tissue. Cultures from the necrotic tissue were negative for *pseudomonas* (the resistant original pathogen). *i.* The granulation tissue seemed to affect the necrotic tissue with autolysis (self-debridement). *j* and *k.* After 5 months of COD treatment, the medial and lateral wounds were closed. *l.* The main wound was partially closed and the rest of the wound was with pink to red granulation tissue.

The foot condition improved gradually. The superficial semi-necrotic ulcer at the heel and lateral aspect of the foot showed gradual absorption of the necrotic tissue, granulation and epithelization (**Figures 5f-i**). The main amputation wound, with large area and volume and inner cavity of 6–7 cm, gradually filled with granulation tissue (**Figure 5g**). The granulation tissue seemed to affect the necrotic tissue with autolysis (self-debridement, **Figure 5i**). New epithelium gradually covered the

healing wounds (**Figure 5g and h**). Microbial culture, taken from the necrotic tissue three months after cessation of antibiotic administration, did not yield pseudomonas, although normal non-pathogenic colonizing bacteria were identified.

After 5 months of COD treatment, the medial and lateral wounds were closed (**Figure 5j and k**). The main wound was partially closed and the rest of the wound was with pink to red granulation tissue (**Figure 5l**).

2.4.2 Increased epithelization

The powerful ability of COD to promote epithelization is illustrated in the following case of a 71 years old man with NIDDM and diabetic neuropathy. The patient had osteomyelitis of the calcaneus, which necessitated extensive debridement of the heel and the infected calcaneus bone. The wound did not heal and the calcaneus broke through area of weakness due to the missing bone, thus creating a rocker deformity. Repeated surgery with debridement of the soft tissue, correction of the foot alignment and fixation with Steinman pins was carried out (**Figure 6a and b**, 1-week

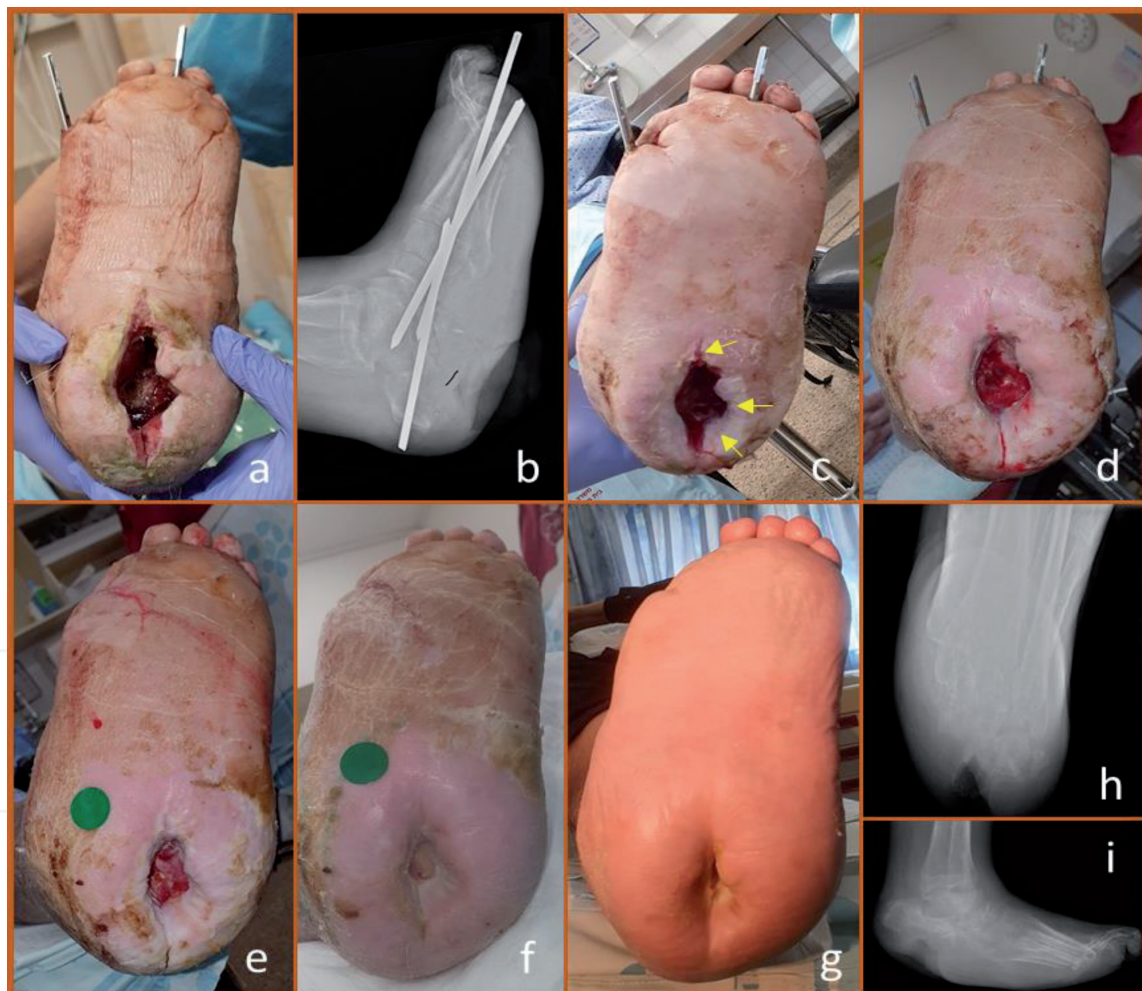


Figure 6.

Epithelization of a rocker deformity related plantar deep wound. The patient had resection of infected calcaneal bone with correction and stabilization of ensuing rocker deformity with Steinman pins. COD was applied at surgery. a. one week following surgery the deep calcaneal wound is evident without signs of infection. b. X-ray showing the inserted Steinman pins. The missing plantar calcaneal bone and the deep soft tissue void underneath can be seen. c. Three weeks post-surgery, following the use of the COD, skin began crawling from the side surface into the depth of the wound. Further coverage of the wound granulation tissue with epidermal tissue is seen after 7 weeks (d), 8 weeks (e) and 3.5 months (f) of COD treatment, resulting in 95% complete closure of the wound at 4.5 months (g). h and i. lateral foot and Axial calcaneal X-rays of the foot 4.5 months after surgery. Although large soft tissue void is prominent, it is filled with practically normal looking skin that crawled in. During all this period the foot was treated solely with COD.

post-surgery). At surgery and thereafter the wound was dressed with COD, which was changed weekly. While relatively rapid granulation seemed to fill the depth and walls of the large cavity, normal looking skin began crawling from the side surface into the depth of the wound. **Figure 6c**, taken 3 weeks post-surgery demonstrated epithelization beginning at the superficial wall of the cavity (arrows). This phenomenon is further demonstrated in the photos taken at 7, 8 weeks (**Figure 6d** and **e**), 3.5- and 4.5-months post-surgery (**Figure 6f** and **g**). The corresponding x-rays at 4.5 months are shown in **Figure 6h** and **i**.

2.4.3 Reduction of post-operative swelling and inflammation

62-year-old man suffered from degenerative changes of the 1st metatarsophalangeal joint (Hallux Rigidus) and metatarsalgia. The forefoot deformities included hallux valgus Interphalangeus, subluxed lesser MTPJ's, hammer 2nd toe and Bunionette deformity (**Figure 7a**). Surgery included cheilectomy of the first metatarsal head, Akin-Moberg osteotomy of the base of the proximal phalanx of the big toe, Weil osteotomies of the 2nd and 3rd metatarsals, Chevron osteotomy of the 5th metatarsal and PIPJ arthrodesis to correct the 2nd hammer toe (**Figure 7b**). The later was fixed with Kirschner wires (KW) and so was the 5th metatarsal. The 2nd and 3rd metatarsals were fixed with a screw and the bog toe proximal phalanx osteotomy was secured with absorbable suture. The foot was dressed with COD immediately after surgery with first dressing change after 3 weeks. At that time, surgical wounds were without any sign of infection or inflammation (**Figure 7c**). Despite having 4 metatarsal osteotomies and one toe arthrodesis in any of these sites, there was no swelling to the degree that normal skin wrinkles could be observed (**Figures 7c-e**). This is in contrast to the usual significant swelling that is observed for several months after foot osteotomies.

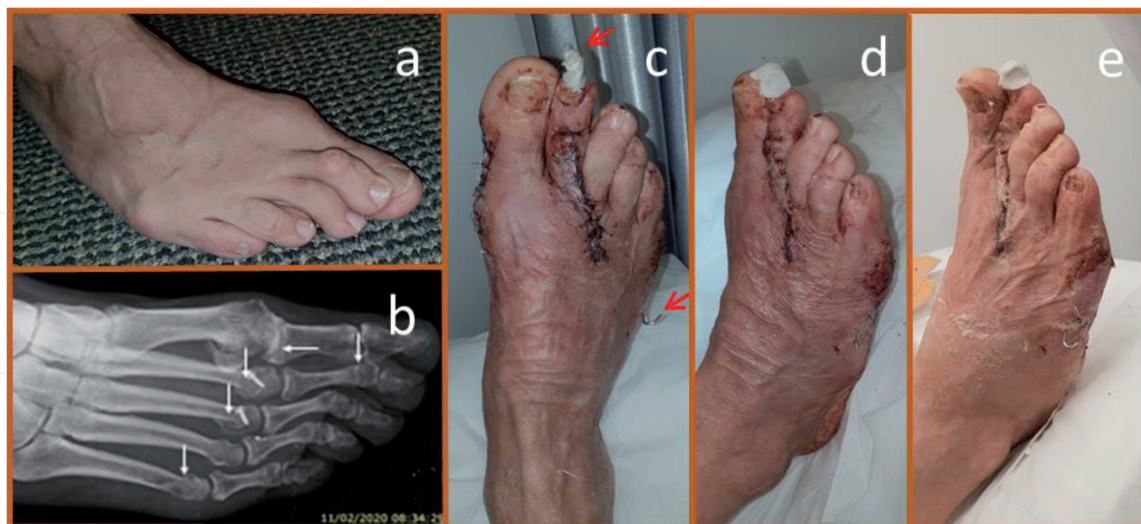

Figure 7. Reduction of swelling after forefoot surgeries and osteotomies. *a.* Forefoot deformities in a 62-year-old man. Hallux valgus, hammer second toe, subluxed 2nd and 3rd metatarsophalangeal joints and Bunionette deformity are observed. *b.* X-ray image taken 2 months after surgery demonstrates osteotomy of the base of the proximal phalanx of the big toe, Weil osteotomies of the 2nd and 3rd metatarsals, Chevron osteotomy of the 5th metatarsal and PIPJ arthrodesis of the 2nd hammer toe (arrows). *c.* Clinical photo of the foot at first dressing change three weeks after surgery (COD dressings were applied during surgery). Surgical wounds are without any sign of inflammation and lack of swelling and skin wrinkles can be seen. The tip of the KW's fixing the 2nd toe and the 5th metatarsal are seen and marked with red arrows (the second toe KW is wrapped with plaster to prevent accidental pullout) *d.* Oblique view of the same foot at the same visit after stitches removal demonstrates clearly the reduction of swelling. *e.* Clinical photos taken at 5 weeks post-surgery. Skin wrinkles and no swelling is again evident.

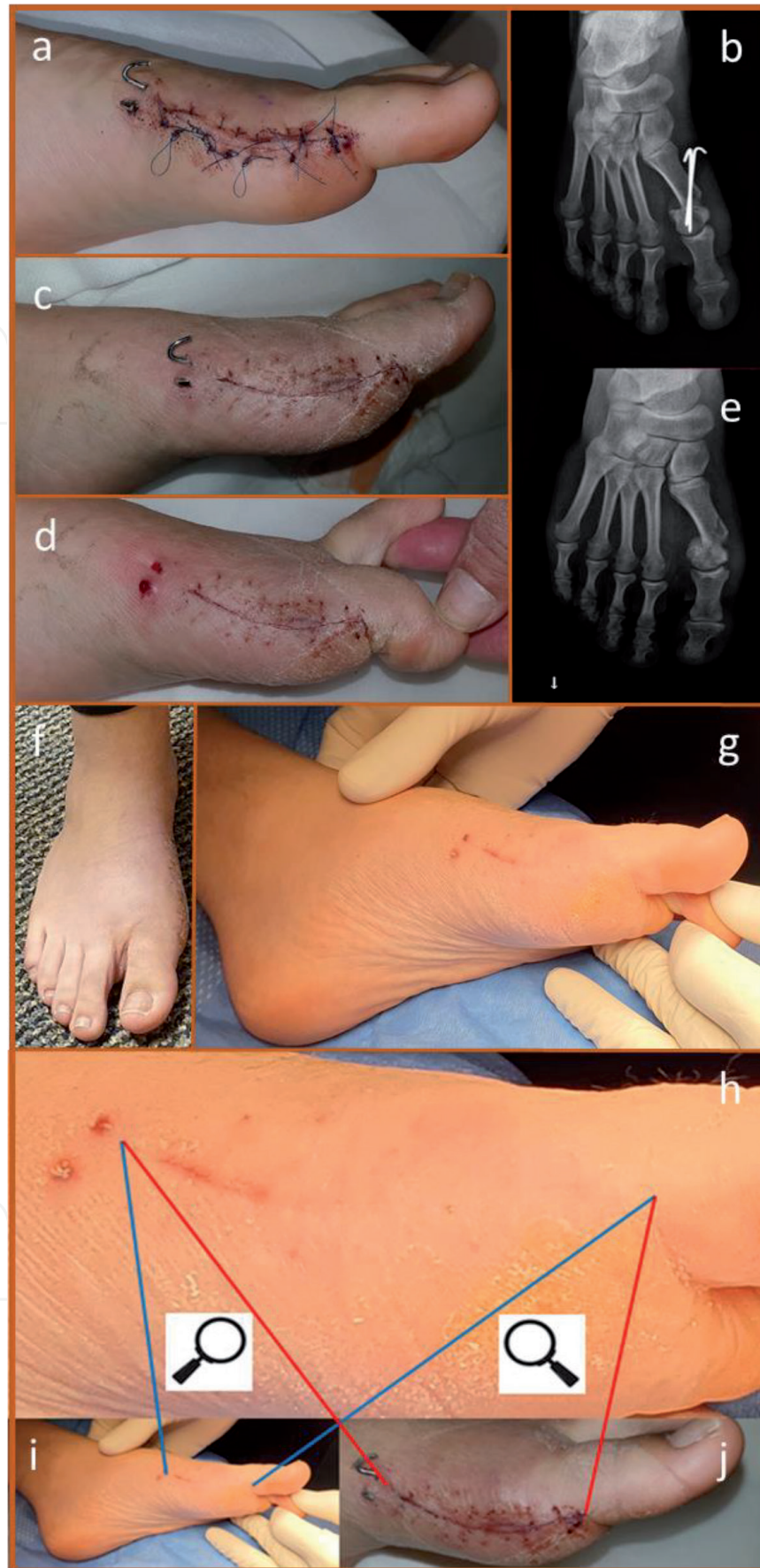

Figure 8.

Reduction of scar formation – Case Report 1. a. Bunion surgery that included Chevron type osteotomy of the 1st metatarsal and fixation with two KW's. b. X-Ray of the foot following surgery. c. Surgical incision appearance at two weeks post-surgery. d. Surgical incision appearance at four weeks post-surgery. e. X-Ray of the foot at 7 weeks post-surgery. f. Clinical appearance of the foot at seven weeks post-surgery. g. Surgical incision appearance at seven weeks post-surgery. h. Enlargement of the surgical site at seven weeks post-surgery. Comparison between the scar appearance after 7 weeks (i) and 2 weeks (j) post-surgery shows that most of the scar has disappeared and was not detectable even at high magnification (h).

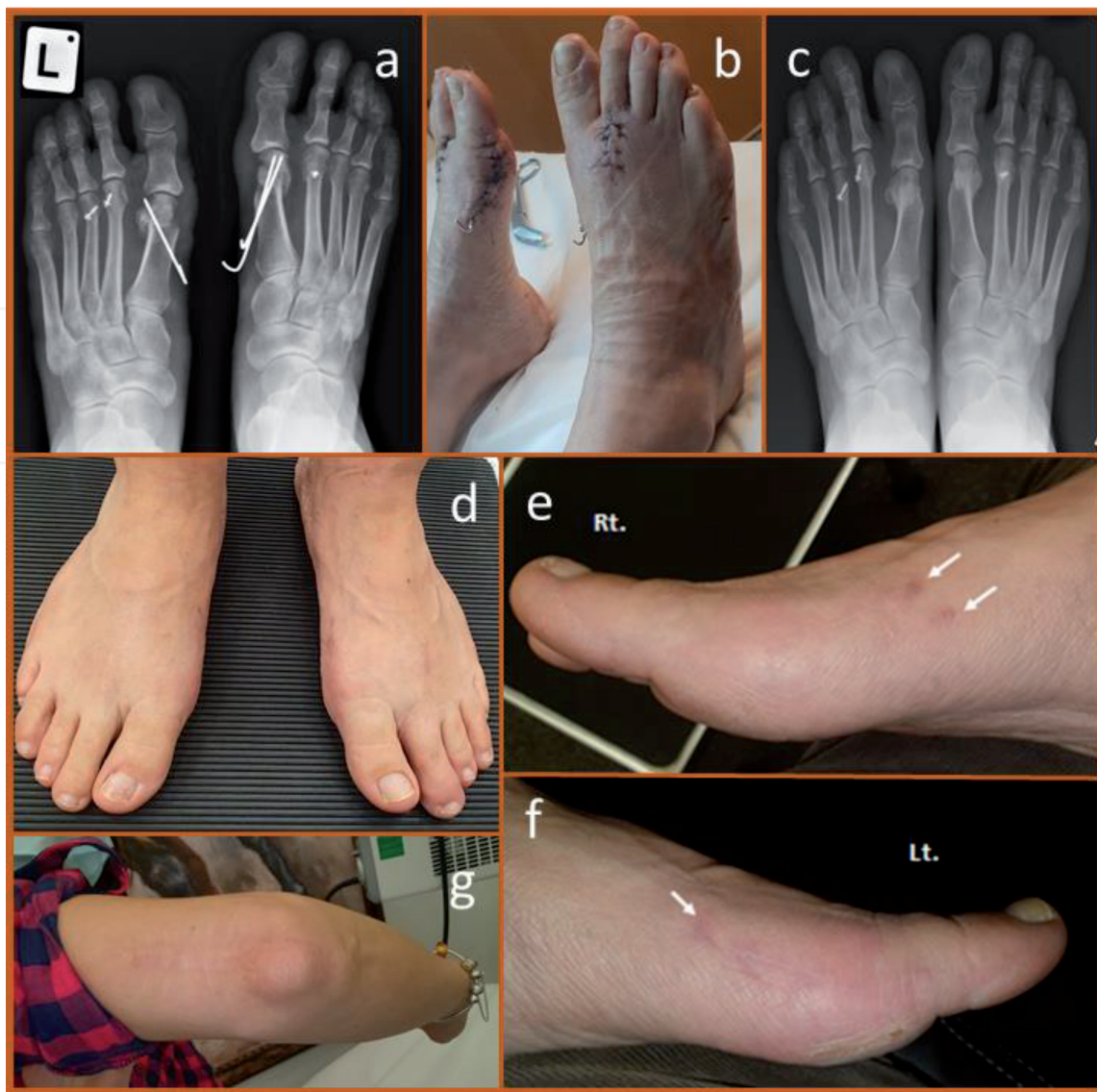

Figure 9.
Reduction of scar formation – Case Report 2. a. X-ray of both feet showing 1st and 2nd metatarsal osteotomy due to hallux valgus and metatarsalgia. b. Surgical incision appearance at 2 weeks post-surgery. c. X-ray and d. photographs of both feet one-year post-surgery showing successful foot positioning. e. Surgical incision appearance of right foot one-year post-surgery. f. Surgical incision appearance of right foot one-year post-surgery. g. Hypertrophic scar 25 years post-surgery due to elbow fracture.

2.4.4 Reduction of scar formation

Reduction of scar formation may be difficult to prove or demonstrate since the final surgical incision healing is a function of surgical technique as well as the patient own tendency to produce hypertrophic scar or even keloid. We have therefore elected to present the reduced scar formation in two cases of bunion surgery. **Figures 8** and **9** with unexpected rapid healing in one patients and very good healing despite basic tendency to hypertrophic scar in another patient.

2.4.4.1 Case report 1

The first one is a 20-year-old healthy woman who had bunion surgery which included Chevron type osteotomy of the 1st metatarsal and fixation with KW (**Figure 8a**). The surgical incision and the KW's are seen at two weeks post-surgery (clinical photos and x-rays, (**Figure 8a** and **b**)). The KW's were removed at 4 weeks. By that time nice healing of the surgical incision seems to have taken place (**Figure 8c** and **d**). At 7-weeks post-surgery, the osteotomy has healed and

clinical appearance is satisfactory (**Figure 8e** and **f**). The surgical scar is very delicate (**Figure 8g**). A comparison between the original incision and its appearance after 7-weeks shows that ~80% of the incision scar is not observed even in high resolution and magnification photography (**Figures 8h-j**). This implies that either direct epithelization has occurred or remodeling of the scar took place. The superb cosmetic results at 7-weeks seems to be beyond a “successful case” and we attribute it to the beneficial effect of copper oxide on wound healing.

2.4.4.2 Case report 2

The second case is of a 49-years-old healthy woman who underwent bilateral hallux valgus surgery, which included distal first metatarsal osteotomy, fixed with KW's and Weil osteotomies of the 2nd (+ 3rd) metatarsals (**Figure 9a**). The feet were dressed with COD. Two weeks post-surgery swelling was minimal and even skin wrinkles could be seen (**Figure 9b**). One year post surgery the foot position is very good (**Figure 9c** and **d**). The dorsal incision scarring is minimal (**Figure 9d**), the medial scar on both feet is hardly visible (**Figure 9e** and **f**). The patient said she has a tendency to create hypertrophic scars, for example a scar following open reduction and internal fixation of elbow fracture 25 year ago (**Figure 9g**).

3. Discussion

Copper is a natural mineral, which is an essential element of nutrition due to its role in many of the physiological processes in all body tissues [12, 13]. We have reviewed the beneficial effect of copper in wound healing based on abundant basic science research as well as our cumulative experience with the use of COD. Copper has been known for its antimicrobial properties including against all common wound pathogens and resistant bacteria. Similar properties are attributed to silver. Indeed, silver-containing wound dressings are widely used in wound treatment to reduce the risk of wound and wound-dressing contamination [43]. It is desirable, of course, to have a wound dressing that also promotes wound healing. Previous research has shown the beneficial effect of copper on skin and integumentary system [14] as well as on wound healing in diabetic mice [41]. The mechanism by which copper exerts its positive roll has been shown to be through up-regulating the level of Hif-1 α , which is a key protein in tissue generation, especially in conditions of ischemia, like in hard to heal wounds. In this regard copper differs from silver, which exerts the opposite effect on wound healing, probably by downregulating Hif-1 α [44]. Therefore, the usefulness of silver-based dressing in promoting wound healing is questionable, among others due to cellular toxicity [45, 46].

However, since copper has potent biocidal properties [37], but in contrast to silver, is an indispensable trace element extremely well metabolized by the human body [12], we hypothesized that it could substitute silver in wound dressings. This would be justified for the goal of reducing bio-contamination. But, even more importantly, are the key roles copper plays in skin generation and angiogenesis. We further hypothesized that the inability of wounds to heal in individuals with compromised peripheral blood supply (e.g., with vascular diseases or diabetics), is partially due to low levels of copper in the wound site [47]. We suggested that by using a copper oxide-containing wound dressing we would slowly release *in situ* copper ions needed for angiogenesis, skin regeneration and wound healing.

Based on the above, we prepared wound dressings containing copper oxide (COD, **Figure 1**). The COD, which possess potent biocidal properties (**Figures 2** and **3**), were found to be safe in animal studies, showing no skin irritation and no local damage to open wounds or systemic pathological alterations in a porcine

full-thickness wound model (unpublished data). Indeed, the risk of adverse reactions due to dermal contact with copper is extremely low [48, 49]. Furthermore, wounds inflicted in diabetic (db/db) mice under sterile conditions and kept covered throughout the study with sterile wound dressings demonstrated a statistically significant enhancement of wound closure when the dressings contained copper oxide [41]. Enhanced wound healing was nearly that anticipated from wild-type mice, where similar full-thickness dorsal skin wounds reach complete closure 7–10 days earlier than in db/db mice [50]. In contrast, commercially-used silver-containing wound dressings did not accelerate wound healing in this model [41]. Following the clearance of the COD to be used clinically, we have found, as described in some representative cases in the article, the significantly better results obtained with the COD than SOC dressings, including silver-based wound dressings.

The demonstrated cases (**Figures 5-9**) show the several effects of COD on different stages and aspects of wounds healing. The effects were reduction of colonized bacteria and superficial infection, as well as increased granulation and epithelization, as demonstrated in **Figure 5**. **Figure 6** shows rapid epithelization of normal looking plantar skin into the cavity underneath the calcaneus. In addition to wound closure, we see in **Figures 7-9** improved healing process on primary closed clean surgical incisions, which expresses itself in improved scar formation and reduces swelling.

Due to the effect of COD on the various stages of wound healing, we now often use the COD continuously during the various phases of wound treatment. For example, we apply them on debrided wounds after partial foot amputation due to diabetic foot infection (instead of povidone-iodine or chlorine based dressings), and as healing progresses, we use them to assist in filling the wound with granulation tissue (for example, instead of using Negative Pressure Wound Therapy (NPWT)). Once the wound has filled with new tissue, we use the COD to help epithelization until full wound closure is achieved.

Another advantage of COD is the few dressing changes it needs, usually once or twice weekly. This makes it convenient to the patient and savvy for the health care system. In the hospital, COD may replace chlorine-based dressings (e.g. Eusol or Daikin solutions), which needs changes 2–3 times daily, and thus reduce the workload on the nursing staff as well as diminishing the risk of spreading resistant bacteria and cross contamination in the Ward.

Additional studies are needed to further elucidate the exact mechanisms by which copper stimulates wound healing. It is clear, however, that copper directly or indirectly stimulates many factors, some of which are impaired in diabetics and are important for keratinocytes and fibroblasts proliferation, epithelization, collagen synthesis, extracellular matrix remodeling and angiogenesis. Indeed, by utilizing COD dressings on chronic wounds, which had failed to heal or healed slowly with other well-recognized wound care protocols, we found improved wound healing kinetics and wound closure in most patients.

4. Conclusions

As demonstrated by the murine diabetic model [41], the positive effect of the copper oxide-containing dressings is not related solely to its potent biocidal properties, but to the direct stimulation of wound repair. No adverse events were recorded with the use of the copper dressings and all patients showed positive response to its application. Thus, copper dressings appear to hold significant promise in the clinician's ongoing struggle to heal both acute and chronic wounds. Additional randomized, controlled studies should be conducted to further validate the efficacy of topically applied copper oxide-impregnated dressings.

IntechOpen

Author details

Gadi Borkow^{1*} and Eyal Melamed²

1 MedCu Technologies Ltd., Herzliya, Israel

2 Foot and Ankle Service, Department of Orthopaedics, Rambam Health Care Campus, Haifa, Israel

*Address all correspondence to: gadib@medcu.com

IntechOpen

© 2021 The Author(s). Licensee IntechOpen. This chapter is distributed under the terms of the Creative Commons Attribution License (<http://creativecommons.org/licenses/by/3.0>), which permits unrestricted use, distribution, and reproduction in any medium, provided the original work is properly cited. 

References

- [1] Richardson M. Acute wounds: an overview of the physiological healing process. *Nurs Times*. 2004;100(4): 50-53.
- [2] Diegelmann RF, Evans MC. Wound healing: an overview of acute, fibrotic and delayed healing. *Front Biosci*. 2004;9:283-289.
- [3] Philips N, Keller T, Gonzalez S. TGF beta-like regulation of matrix metalloproteinases by anti-transforming growth factor-beta, and anti-transforming growth factor-beta 1 antibodies in dermal fibroblasts: Implications for wound healing. *Wound Repair Regen*. 2004;12(1):53-59.
- [4] Sorrell JM, Baber MA, Caplan AI. Clonal characterization of fibroblasts in the superficial layer of the adult human dermis. *Cell Tissue Res*. 2007;327(3):499-510.
- [5] Gailit J, Clarke C, Newman D, Tonnesen MG, Mosesson MW, Clark RA. Human fibroblasts bind directly to fibrinogen at RGD sites through integrin alpha(v)beta3. *Exp Cell Res*. 1997;232(1):118-126.
- [6] Kornblatt AP, Nicoletti VG, Travaglia A. The neglected role of copper ions in wound healing. *J Inorg Biochem*. 2016;161:1-8.
- [7] Ferreira MC, Tuma P, Jr., Carvalho VF, Kamamoto F. Complex wounds. *Clinics*. 2006;61(6):571-578.
- [8] Bowering CK. Diabetic foot ulcers. Pathophysiology, assessment, and therapy. *Can Fam Physician*. 2001;47:1007-1016.
- [9] Abbade LP, Lastoria S. Venous ulcer: epidemiology, physiopathology, diagnosis and treatment. *Int J Dermatol*. 2005;44(6):449-456.
- [10] Coelho S, Amarelo M, Ryan S, Reddy M, Sibbald RG. Rheumatoid arthritis-associated inflammatory leg ulcers: a new treatment for recalcitrant wounds. *Int Wound J*. 2004;1(1):81-84.
- [11] Cullum N, Nelson EA, Nixon J. Pressure ulcers. *Clin Evid*. 2006;(15): 2592-2606.
- [12] Uauy R, Olivares M, Gonzalez M. Essentiality of copper in humans. *Am J Clin Nutr*. 1998;67(5 Suppl):952S-959S.
- [13] Vetchy MPJV. Biological role of copper as an essential trace element in the human organism. *Ceska Slov Farm*. 2018;67(4):143-153.
- [14] Polefka TG, Bianchini RJ, Shapiro S. Interaction of mineral salts with the skin: a literature survey. *Int J Cosmet Sci*. 2012;34(5):416-423.
- [15] Ozumi K, Sudhakar V, Kim HW, Chen GF, Kohno T, Finney L, Vogt S, McKinney RD, Ushio-Fukai M, Fukai T. Role of copper transport protein antioxidant 1 in angiotensin II-induced hypertension: a key regulator of extracellular superoxide dismutase. *Hypertension*. 2012;60(2):476-486.
- [16] Tsai CY, Finley JC, Ali SS, Patel HH, Howell SB. Copper influx transporter 1 is required for FGF, PDGF and EGF-induced MAPK signaling. *Biochem Pharmacol*. 2012;84(8):1007-1013.
- [17] Sen CK, Khanna S, Venojarvi M, Trikha P, Ellison EC, Hunt TK, Roy S. Copper-induced vascular endothelial growth factor expression and wound healing. *Am J Physiol Heart Circ Physiol*. 2002;282(5):H1821-H1827.
- [18] Prudovsky I, Mandinova A, Soldi R, Bagala C, Graziani I, Landriscina M, Tarantini F, Duarte M, Bellum S, Doherty H, Maciag T. The non-classical export routes: FGF1 and IL-1alpha

point the way. *J Cell Sci.* 2003;116(Pt 24):4871-4881.

[19] Philips N, Samuel P, Parakandi H, Gopal S, Siomyk H, Ministro A, Thompson T, Borkow G. Beneficial regulation of fibrillar collagens, heat shock protein-47, elastin fiber components, transforming growth factor-beta1, vascular endothelial growth factor and oxidative stress effects by copper in dermal fibroblasts. *Connect Tissue Res.* 2012;53(5):373-378.

[20] Mandinov L, Mandinova A, Kyurkchiev S, Kyurkchiev D, Kehayov I, Kolev V, Soldi R, Bagala C, de Muinck ED, Lindner V, Post MJ, Simons M, Bellum S, Prudovsky I, Maciag T. Copper chelation represses the vascular response to injury. *Proc Natl Acad Sci U S A.* 2003; 00(11):6700-6705.

[21] Parke A, Bhattacharjee P, Palmer RM, Lazarus NR. Characterization and quantification of copper sulfate-induced vascularization of the rabbit cornea. *Am J Pathol.* 1988;130(1):173-178.

[22] Narayanan G, BS R, Vuyyuru H, Muthuvel B, Konerirajapuram NS. CTR1 silencing inhibits angiogenesis by limiting copper entry into endothelial cells. *PLoS One.* 2013;8(9):e71982.

[23] La MD, Arnesano F, Hansson O, Giacomelli C, Calo V, Mangini V, Magri A, Bellia F, Trincavelli ML, Martini C, Natile G, Rizzarelli E. Copper binding to naturally occurring, lactam form of angiogenin differs from that to recombinant protein, affecting their activity. *Metallomics.* 2016;8(1):118-124.

[24] Ogen-Shtern N, Chumin K, Cohen G, Borkow G. Increased pro-collagen 1, elastin, and TGF-beta1 expression by copper ions in an ex-vivo human skin model. *J Cosmet Dermatol.* 2020;19(6):1522-1527.

[25] Gerard C, Bordeleau LJ, Barralet J, Doillon CJ. The stimulation

of angiogenesis and collagen deposition by copper. *Biomaterials.* 2010;31(5):824-831.

[26] Rucker RB, Kosonen T, Clegg MS, Mitchell AE, Rucker BR, Uriu-Hare JY, Keen CL. Copper, lysyl oxidase, and extracellular matrix protein cross-linking. *Am J Clin Nutr.* 1998;67(5 Suppl):996S-1002S.

[27] Sajithlal GB, Chithra P, Chandrakasan G. An in vitro study on the role of metal catalyzed oxidation in glycation and crosslinking of collagen. *Mol Cell Biochem.* 1999;194(1-2):257-263.

[28] Kothapalli CR, Ramamurthi A. Copper nanoparticle cues for biomimetic cellular assembly of crosslinked elastin fibers. *Acta Biomater.* 2009;5(2):541-553.

[29] Tenaud I, Sainte-Marie I, Jumbou O, Litoux P, Dreno B. In vitro modulation of keratinocyte wound healing integrins by zinc, copper and manganese. *Br J Dermatol.* 1999;140(1):26-34.

[30] Das A, Sudhakar V, Chen GF, Kim HW, Youn SW, Finney L, Vogt S, Yang J, Kweon J, Surenkhuu B, Ushio-Fukai M, Fukai T. Endothelial Antioxidant-1: a Key Mediator of Copper-dependent Wound Healing in vivo. *Sci Rep.* 2016;6:33783.

[31] Edwards R, Harding KG. Bacteria and wound healing. *Curr Opin Infect Dis.* 2004;17(2):91-96.

[32] Ovington L. Bacterial toxins and wound healing. *Ostomy Wound Manage.* 2003;49(7A Suppl):8-12.

[33] Robson MC, Stenberg BD, Hegggers JP. Wound healing alterations caused by infection. *Clin Plast Surg.* 1990;17(3):485-492.

[34] Laato M, Niinikoski J, Lundberg C, Gerdin B. Inflammatory reaction and

- blood flow in experimental wounds inoculated with *Staphylococcus aureus*. *Eur Surg Res*. 1988;20(1):33-38.
- [35] Hodgkinson V, Petris MJ. Copper homeostasis at the host-pathogen interface. *J Biol Chem*. 2012;287(17):13549-13555.
- [36] Porcheron G, Garenaux A, Proulx J, Sabri M, Dozois CM. Iron, copper, zinc, and manganese transport and regulation in pathogenic *Enterobacteria*: correlations between strains, site of infection and the relative importance of the different metal transport systems for virulence. *Front Cell Infect Microbiol*. 2013;3:90.
- [37] Borkow G, Gabbay J. Copper as a biocidal tool. *Curr Med Chem*. 2005;12(18):2163-2175.
- [38] Borkow G. Using copper to fight microorganisms. *Curr Chem Biol*. 2012;6(2):93-103.
- [39] Kumar A, Pandit V, Nagaich U. Therapeutic evaluation of chemically synthesized copper nanoparticles to promote full-thickness excisional wound healing. *Int J Applied Pharmaceutics*. 2020;12(6):136-142.
- [40] Ghosh D, Godeshala S, Nitiyanandan R, Islam MS, Yaron JR, DiCaudo D, Kilbourne J, Rege K. Copper-Eluting Fibers for Enhanced Tissue Sealing and Repair. *ACS Appl Mater Interfaces*. 2020;12(25):27951-27960.
- [41] Borkow G, Gabbay J, Dardik R, Eidelman AI, Lavie Y, Grunfeld Y, Ikher S, Huszar M, Zatzoff RC, Marikovsky M. Molecular mechanisms of enhanced wound healing by copper oxide-impregnated dressings. *Wound Repair Regen*. 2010;18(2):266-275.
- [42] Scherer SS, Pietramaggiori G, Mathews JC, Chan R, Fiorina P, Orgill DP. Wound healing kinetics of the genetically diabetic mice. *Wounds*. 2008;20(1):18-28.
- [43] Leaper DJ. Silver dressings: their role in wound management. *Int Wound J*. 2006;3(4):282-294.
- [44] Yang T, Yao Q, Cao F, Liu Q, Liu B, Wang XH. Silver nanoparticles inhibit the function of hypoxia-inducible factor-1 and target genes: insight into the cytotoxicity and antiangiogenesis. *Int J Nanomedicine*. 2016;11:6679-6692.
- [45] Atiyeh BS, Costagliola M, Hayek SN, Dibo SA. Effect of silver on burn wound infection control and healing: review of the literature. *Burns*. 2007;33(2):139-148.
- [46] Chambers H, Dumville JC, Cullum N. Silver treatments for leg ulcers: a systematic review. *Wound Repair Regen*. 2007;15(2):165-173.
- [47] Borkow G, Gabbay J, Zatzoff RC. Could chronic wounds not heal due to too low local copper levels? *Med Hypotheses*. 2008;70(3):610-613.
- [48] Hostynek JJ, Maibach HI. Copper hypersensitivity: dermatologic aspects-an overview. *Rev Environ Health*. 2003;18(3):153-183.
- [49] Gorter RW, Butorac M, Cobian EP. Examination of the cutaneous absorption of copper after the use of copper-containing ointments. *Am J Ther*. 2004;11(6):453-458.
- [50] Chan RK, Liu PH, Pietramaggiori G, Ibrahim SI, Hechtman HB, Orgill DP. Effect of recombinant platelet-derived growth factor (Regranex) on wound closure in genetically diabetic mice. *J Burn Care Res*. 2006;27(2):202-205.

NATURE + SCIENCE = BETTER WOUND CARE

MedCu's antimicrobial wound dressings harness the power of copper to set a new standard in wound care.

As a natural essential mineral for the human body, copper has been used for centuries to care for and treat wounds. Today, copper is at the forefront of a revolution in advanced wound care. MedCu is the first and only antimicrobial wound dressing impregnated with copper oxide microparticles to receive FDA clearance and CE Mark.


MedCu wound dressings offer protection against a broad spectrum of pathogens, including antibiotic-resistant bacteria. The dressings are non-adherent, with no need to pre-wet, and can be cut to ensure optimal fit for patient comfort. With sustained antimicrobial action, the dressings have up to 7 day wear-time allowing for fewer changes and reduced clinician contact time.

MedCu allows clinicians to effectively and efficiently care for wounds towards complete healing.

Areas of Use

MedCu's wound dressings are easy to apply and remove, and are suitable for a wide variety of applications including:

- Diabetic Wounds
- Leg & Foot Ulcers
- Pressure Ulcers
- First and Second-Degree Burns
- Surgical Wounds



SKU	Size inches	Size cm	Absorption Weight/Weight	Adhesive Contour
2C-0506-01	2x2.4	5x6	750%	-
2C-1012-01	4x4.5	10x12	1000%	-
2C-1020-01	4x8	10x20	1000%	-
2C-2020-01	8x8	20x20	1000%	-
2C-0505-01a	4x4 Pad: 2.5x2.5	10x10 Pad: 5x5	750%	+
2C-1025-01a	4x10 Pad: 4x7.8	10x25 Pad: 5x20	750%	+
3C-1012-01	4x4.5	10x12	800%	-